

REVIEW ARTICLE

CURRENT CONCEPTS

Edward W. Campion, M.D., *Editor*

Diagnostic Criteria for Nonviable Pregnancy Early in the First Trimester

Peter M. Doubilet, M.D., Ph.D., Carol B. Benson, M.D.,
Tom Bourne, M.B., B.S., Ph.D., and Michael Blaivas, M.D., for the Society of
Radiologists in Ultrasound Multispecialty Panel on Early First Trimester Diagnosis
of Miscarriage and Exclusion of a Viable Intrauterine Pregnancy*

OVER THE PAST TWO TO THREE DECADES, PELVIC ULTRASONOGRAPHY and measurement of the serum concentration of human chorionic gonadotropin (hCG) (Table 1) have become mainstays in the diagnosis and management of early-pregnancy problems. These tests, which allow earlier detection of pregnancy and more accurate diagnosis of its complications than were previously possible, have revolutionized the management of intrauterine pregnancies and markedly reduced the morbidity and mortality associated with ectopic pregnancy.^{1,2}

Although these tests have indisputable benefits, their misuse and misinterpretation can lead to interventions that inadvertently damage pregnancies that might have had normal outcomes.^{3,4} There are well-documented instances of women with intrauterine pregnancies treated with intramuscular methotrexate for suspected ectopic pregnancy, leading to failure of the pregnancy (“miscarriage”) or the birth of a malformed baby.⁵ Furthermore, considerable evidence suggests that mistakes such as these are far from rare. Malpractice lawsuits related to this type of error constitute “a rapidly increasing source of medical liability actions,”⁶ and there are online support groups for women erroneously treated in this manner.⁷

When a woman presents with symptoms of pain or bleeding in early pregnancy, the main diagnostic possibilities are a currently viable intrauterine pregnancy, a failed (or failing) intrauterine pregnancy, and ectopic pregnancy. Serum hCG measurement and pelvic ultrasonography are commonly performed to aid in the differential diagnosis. At that point, unless a life-threatening situation dictates immediate management, a key question is: “Is there a chance of a viable pregnancy?” (Table 1). This question is central to management decision making in two main clinical contexts: intrauterine pregnancy of uncertain viability and pregnancy of unknown location (Table 1). For a woman with an intrauterine pregnancy of uncertain viability, the answer to this question is central in deciding whether to evacuate the uterus. For a woman with a pregnancy of unknown location, the answer plays an important role in deciding whether to initiate treatment for a suspected ectopic pregnancy.

A pregnancy is diagnosed as nonviable if it meets one of the commonly accepted positivity criteria for that diagnosis, such as the embryonic size at which nonvisualization of a heartbeat on ultrasonography is diagnostic of failed pregnancy. The positivity criterion for any diagnostic test should depend, in part, on the downstream consequences of false positive and false negative diagnoses.⁸ In diagnosing nonviability of an early pregnancy, a false positive diagnosis — erroneously diagnosing nonviability — carries much worse consequences than a false

From Brigham and Women’s Hospital and Harvard Medical School, Boston (P.M.D., C.B.B.); Queen Charlotte’s and Chelsea Hospital, Imperial College, London (T.B.); and the University of South Carolina, Columbia (M.B.). Address reprint requests to Dr. Doubilet at the Department of Radiology, Brigham and Women’s Hospital, 75 Francis St., Boston, MA 02115, or at pdoubilet@partners.org.

*The other authors and members of the panel are Kurt T. Barnhart, M.D., M.S.C.E., Perelman School of Medicine at the University of Pennsylvania, Philadelphia; Beryl R. Benacerraf, M.D., Brigham and Women’s Hospital and Harvard Medical School, Boston; Douglas L. Brown, M.D., Mayo Clinic, Rochester, MN; Roy A. Filly, M.D., University of California, San Francisco, San Francisco; J. Christian Fox, M.D., University of California, Irvine, Irvine; Steven R. Goldstein, M.D., New York University School of Medicine, New York; John L. Kendall, M.D., Denver Health Medical Center, Denver; Edward A. Lyons, M.D., Health Sciences Center, University of Manitoba, Winnipeg, MB, Canada; Misty Blanchette Porter, M.D., Geisel School of Medicine at Dartmouth, Hanover, NH; Dolores H. Pretorius, M.D., University of California, San Diego, San Diego; and Ilan E. Timor-Tritsch, M.D., New York University School of Medicine, New York.

N Engl J Med 2013;369:1443-51.

DOI: 10.1056/NEJMra1302417

Copyright © 2013 Massachusetts Medical Society.

Table 1. Terminology and Diagnostic Tests Used Early in the First Trimester of Pregnancy.

Terminology	Comments
Viable	A pregnancy is viable if it can potentially result in a liveborn baby.
Nonviable	A pregnancy is nonviable if it cannot possibly result in a liveborn baby. Ectopic pregnancies and failed intrauterine pregnancies are nonviable.
Intrauterine pregnancy of uncertain viability	A woman is considered to have an intrauterine pregnancy of uncertain viability if transvaginal ultrasonography shows an intrauterine gestational sac with no embryonic heartbeat (and no findings of definite pregnancy failure).*
Pregnancy of unknown location	A woman is considered to have a pregnancy of unknown location if she has a positive urine or serum pregnancy test and no intrauterine or ectopic pregnancy is seen on transvaginal ultrasonography.
Diagnostic tests	
Human chorionic gonadotropin (hCG)	Serum hCG concentration is measured with the use of the World Health Organization 3rd or 4th International Standard. A positive serum pregnancy test is defined by a serum hCG concentration above a positivity threshold (5 mIU/ml).
Pelvic ultrasonography†	Minimum quality criteria include transvaginal assessment of the uterus and adnexa and transabdominal evaluation for free intraperitoneal fluid and a mass high in the pelvis; oversight provided by an appropriately trained physician; scans performed by providers and interpreted by physicians, all of whom meet at least minimum training or certification standards for ultrasonography, including transvaginal ultrasonography; and scanning equipment permitting adequate visualization of structures early in the first trimester.

* In a woman with a positive urine or serum pregnancy test, an intrauterine fluid collection with rounded edges containing no yolk sac or embryo is most likely a gestational sac; it is certain to be a gestational sac if it contains a yolk sac or embryo.

† Transabdominal imaging without transvaginal scanning may be sufficient for diagnosing early pregnancy failure when an embryo whose crown–rump length is 15 mm or more has no visible cardiac activity.

negative diagnosis — failing to diagnose a pregnancy as nonviable. For either an intrauterine pregnancy of uncertain viability or a pregnancy of unknown location, the consequence of a false positive diagnosis of nonviability may be dire: medical or surgical intervention that eliminates or severely damages a viable pregnancy. This is much worse than the consequence of a false negative diagnosis in women with an intrauterine pregnancy of uncertain viability: a delay (usually by a few days) in intervention for a failed pregnancy. Likewise, for a pregnancy of unknown location, harming a potentially normal intrauterine pregnancy is considerably worse than the possible consequence of a false negative diagnosis: a short delay in treatment of an ectopic pregnancy in a woman who is being followed medically and has no ultrasonographically identifiable adnexal mass.

Thus, the criteria for diagnosing nonviability in early pregnancy should virtually eliminate false positive results. That is, the goal is a specificity of 100%, which yields a positive predictive value of 100% for nonviability, regardless of the

prior probability of that diagnosis. We recognize that this goal cannot always be achieved in clinical practice because of the dependence of ultrasonography on the expertise of the operator and because of statistical limitations in ruling out very rare events. However, we are confident that current data allow us to achieve a specificity extremely close to 100%. Although it would be ideal to have both high sensitivity and high specificity, diagnosis of early pregnancy failure requires a focus on the latter at the expense of the former.^{4,9}

Research in the past 2 to 3 years^{10–12} has shown that previously accepted criteria for ruling out a viable pregnancy, which were based on small numbers of patients,⁹ are not stringent enough to avoid false positive test results. Dissemination of this new information to practitioners and the achievement of standardized practice protocols are challenging, because the diagnosis and management of early-pregnancy complications involve physicians from multiple specialties, including radiology, obstetrics and gynecology, emergency medicine, and family medicine. As a result, there

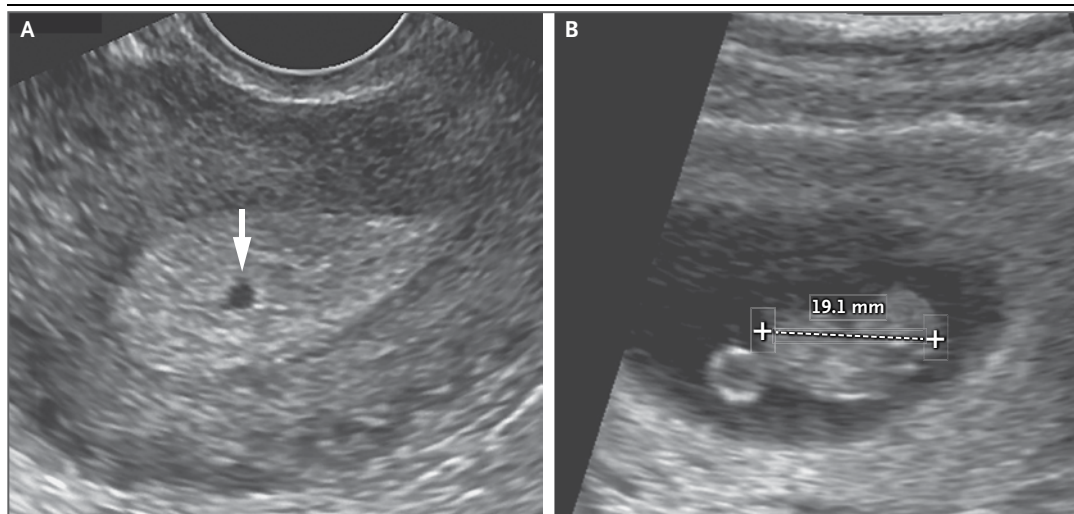


Figure 1. Early Intrauterine Gestational Sac.

A transvaginal ultrasonogram obtained at 5 weeks of gestation (Panel A) shows a small, round, fluid-filled structure (arrow), which was confirmed to be an early intrauterine pregnancy 4 weeks later (Panel B) on a follow-up scan showing a fetus measuring 19.1 mm, corresponding to approximately 9 weeks of gestational age. Plus signs indicate calipers.

is a patchwork of sometimes conflicting, often outdated published recommendations and guidelines from professional societies.¹³

In this review, we examine the diagnosis of nonviability in early intrauterine pregnancy of uncertain viability and in early pregnancy of unknown location separately, focusing mainly on the initial (or only) ultrasonographic study performed during the pregnancy. Our recommendations are meant to apply to any practice, subspecialty or community-based, that meets at least the minimum quality criteria for pelvic ultrasonography listed in Table 1.

DIAGNOSING PREGNANCY FAILURE IN AN INTRAUTERINE PREGNANCY OF UNCERTAIN VIABILITY

The sequence of events in early pregnancy, as seen on transvaginal ultrasonography, follows a fairly predictable pattern. The gestational sac is first seen at approximately 5 weeks of gestational age,^{14,15} appearing as a small cystic-fluid collection with rounded edges and no visible contents, located in the central echogenic portion of the uterus (i.e., within the decidua). Previously described ultrasonographic signs of early pregnancy — the “double sac sign”¹⁶ and “intradecidual sign”¹⁷ — were defined with the use of transabdominal ultrasonography, but with current transvaginal

ultrasonographic technology, these signs are absent in at least 35% of gestational sacs.¹⁸ Therefore, any round or oval fluid collection in a woman with a positive pregnancy test most likely represents an intrauterine gestational sac (Fig. 1)^{19,20} and should be reported as such; it is much less likely to be a pseudogestational sac or decidual cyst, findings that can be present in a woman with an ectopic pregnancy.^{21,22}

The yolk sac, a circular structure about 3 to 5 mm in diameter, makes its appearance at about 5½ weeks of gestation. The embryo is first seen adjacent to the yolk sac at about 6 weeks, at which time the heartbeat is present as a flickering motion.^{14,15}

Variations from the expected pattern of development are worrisome or, if major, definitive for early pregnancy failure. The criteria most often used to diagnose pregnancy failure are the absence of cardiac activity by the time the embryo has reached a certain length (crown–rump length), the absence of a visible embryo by the time the gestational sac has grown to a certain size (mean sac diameter), and the absence of a visible embryo by a certain point in time.

CROWN–RUMP LENGTH AS A CRITERION FOR FAILED PREGNANCY

Shortly after transvaginal ultrasonography became widely available in the mid-to-late 1980s,

Table 2. Guidelines for Transvaginal Ultrasonographic Diagnosis of Pregnancy Failure in a Woman with an Intrauterine Pregnancy of Uncertain Viability.*

Findings Diagnostic of Pregnancy Failure	Findings Suspicious for, but Not Diagnostic of, Pregnancy Failure†
Crown–rump length of ≥ 7 mm and no heartbeat	Crown–rump length of < 7 mm and no heartbeat
Mean sac diameter of ≥ 25 mm and no embryo	Mean sac diameter of 16–24 mm and no embryo
Absence of embryo with heartbeat ≥ 2 wk after a scan that showed a gestational sac without a yolk sac	Absence of embryo with heartbeat 7–13 days after a scan that showed a gestational sac without a yolk sac
Absence of embryo with heartbeat ≥ 11 days after a scan that showed a gestational sac with a yolk sac	Absence of embryo with heartbeat 7–10 days after a scan that showed a gestational sac with a yolk sac
	Absence of embryo ≥ 6 wk after last menstrual period
	Empty amnion (amnion seen adjacent to yolk sac, with no visible embryo)
	Enlarged yolk sac (> 7 mm)
	Small gestational sac in relation to the size of the embryo (< 5 mm difference between mean sac diameter and crown–rump length)

* Criteria are from the Society of Radiologists in Ultrasound Multispecialty Consensus Conference on Early First Trimester Diagnosis of Miscarriage and Exclusion of a Viable Intrauterine Pregnancy, October 2012.

† When there are findings suspicious for pregnancy failure, follow-up ultrasonography at 7 to 10 days to assess the pregnancy for viability is generally appropriate.

several studies sought to determine the cutoff value for crown–rump length above which cardiac activity is consistently visible on transvaginal ultrasonography in a viable pregnancy. The cutoff values identified in these studies were 4 mm^{23,24} and 5 mm.^{25,26} Despite the small number of patients in these studies, a crown–rump length of 5 mm was widely recommended as a positivity criterion for diagnosing failed pregnancy when no cardiac activity is seen.^{27–31}

Although the raw data from some of these studies suggest that a 5-mm cutoff for crown–rump length has a specificity of 100% and a sensitivity of approximately 50%, a systematic review of the literature concluded that, because of the small numbers of patients, the 95% confidence interval for specificity was fairly wide: 90 to 100%.⁹ This indicates that there is a substantial likelihood that a 5-mm cutoff can result in a false positive diagnosis of pregnancy failure. It is therefore not surprising that recent studies involving many more patients have described several embryos with a crown–rump length of 5 to 6 mm and no cardiac activity that subsequently proved to be viable.^{10,11} It has also been shown that the interobserver variation in the measurement of crown–rump length is $\pm 15\%$.³² Thus, a crown–rump length of 6 mm (the upper limit above) as measured by one practitioner may be 15% greater, or 6.9 mm, when measured by another practitioner.

These recent studies suggest that it is prudent

to use a cutoff of 7 mm (rather than 5 mm) for crown–rump length with no cardiac activity (Table 2) for diagnosing failed pregnancy (Fig. 2A). This would yield a specificity and positive predictive value of 100% (or as close to 100% as can be determined). Because cardiac activity is usually visible as soon as an embryo is detectable, the finding of no heartbeat with a crown–rump length of less than 7 mm is suspicious for, though not diagnostic of, failed pregnancy (see video and Fig. S1 in the Supplementary Appendix, both available with the full text of this article at NEJM.org).^{10,23,25}

MEAN SAC DIAMETER AS A CRITERION FOR FAILED PREGNANCY

The size of the gestational sac, measured as the mean sac diameter (the average of the sagittal, transverse, and anteroposterior diameters of the sac), increases as pregnancy progresses. A number of studies have examined the cutoff value for the mean sac diameter above which an embryo is consistently visible on transvaginal ultrasonography in a normal pregnancy. Initial studies involving small numbers of patients put the cutoff value at 16 mm³³ and 17 mm,³⁴ leading to the widespread use of a mean sac diameter of 16 mm as a positivity criterion for diagnosing failed pregnancy when no embryo is seen.^{29–31}

The raw data from these early studies suggest that a 16-mm cutoff for the mean sac diameter has a specificity of 100% and a sensitivity of approximately 50%, but a systematic review of the



A video showing real-time ultrasonography of an embryo is available at NEJM.org

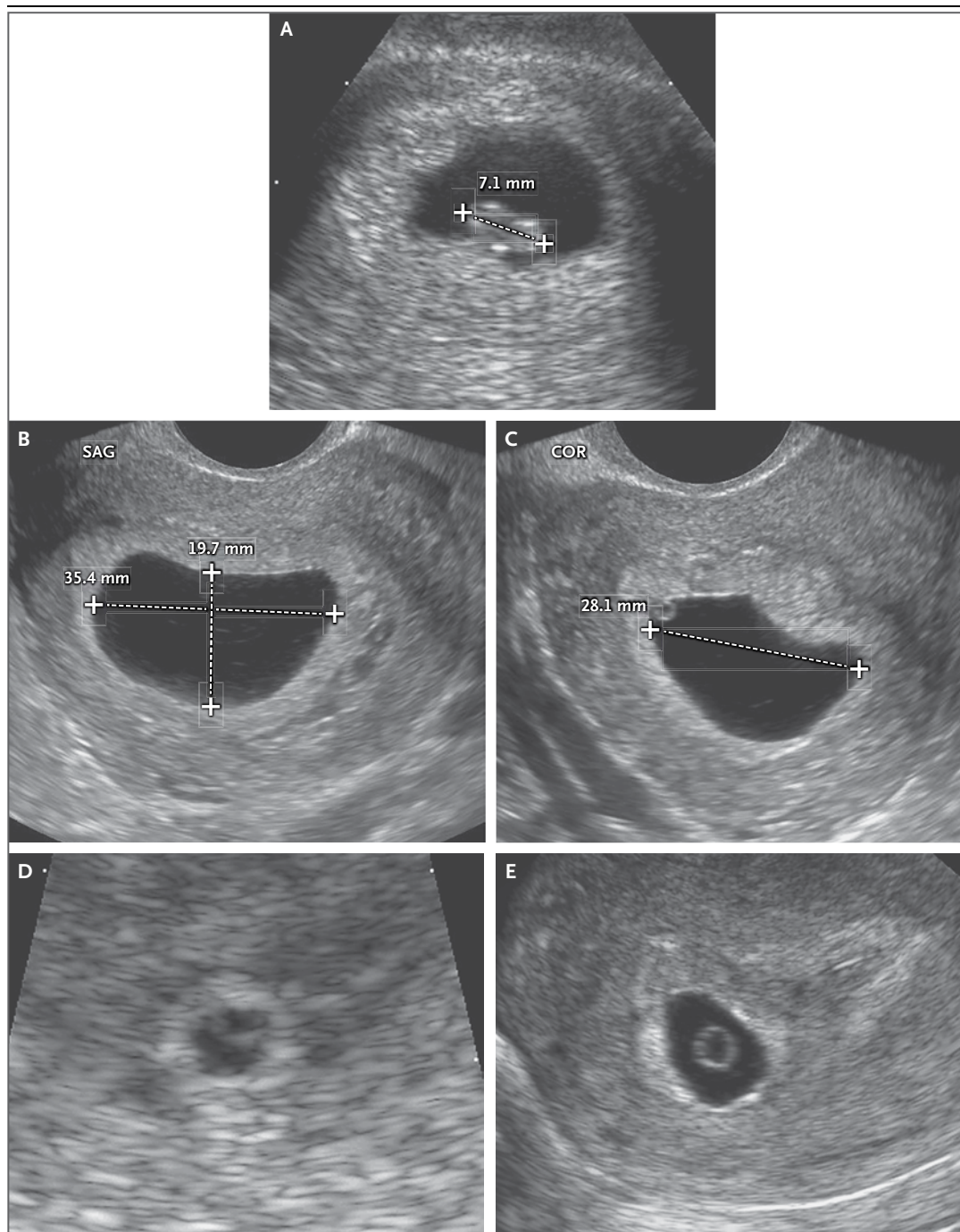


Figure 2. Definite Pregnancy Failure Diagnosed in Three Women by Means of Transvaginal Ultrasonography.

Panel A shows an embryo with a crown–rump length (between the plus signs, indicating calipers) of 7.1 mm. No cardiac activity was seen on real-time ultrasonography. Panels B and C show a gestational sac with a mean diameter of 27.7 mm (average of 35.4 mm, 19.7 mm, and 28.1 mm), with no visible embryo. SAG denotes sagittal view, and COR coronal view. Panel D shows an intrauterine gestational sac with a yolk sac, and Panel E (a scan obtained 2 weeks later) shows a yolk sac but no embryo within the gestational sac.

literature concluded that, because of the small numbers of patients, the 95% confidence interval for specificity is fairly wide: 88 to 100%.⁹ A num-

ber of studies have described gestational sacs with a mean diameter of 17 to 21 mm and no visible embryo that subsequently proved to be viable

pregnancies.^{10,35} In addition, the interobserver variation in the measurement of the mean sac diameter is $\pm 19\%$,³² so a diameter of 21 mm (the upper limit above) as measured by one observer may be 19% greater, or 25 mm, when measured by another observer.

These studies, in combination, suggest that it is prudent to use a cutoff of 25 mm (rather than 16 mm) for the mean sac diameter with no visible embryo (Table 2) in diagnosing failed pregnancy (Fig. 2B and 2C). This would yield a specificity and positive predictive value of 100% (or as close to 100% as can be determined). When the mean sac diameter is 16 to 24 mm, the lack of an embryo is suspicious for, though not diagnostic of, failed pregnancy (Fig. S2 in the Supplementary Appendix).

TIME-BASED CRITERIA FOR FAILED PREGNANCY

Not all failed pregnancies ever develop a 7-mm embryo or a 25-mm gestational sac, so it is important to have other criteria for diagnosing pregnancy failure. The most useful of such criteria involve nonvisualization of an embryo by a certain point in time. An alternative approach to predicting pregnancy failure, based on subnormal growth of the gestational sac and embryo, has been shown to be unreliable.³⁶

Nonvisualization of an embryo with a heartbeat by 6 weeks after the last menstrual period is suspicious for failed pregnancy, but dating of the last menstrual period (in a pregnancy conceived without medical assistance) is too unreliable for definitive diagnosis of pregnancy failure.³⁷ The timing of events in early pregnancy — gestational sac at 5 weeks, yolk sac at 5½ weeks, and embryo with heartbeat at 6 weeks — is accurate and reproducible, with a variation of about $\pm 1/2$ week^{14,15}; this consistency explains the time-related criteria for pregnancy failure listed in Table 2. For example, if the initial ultrasonogram shows a gestational sac with a yolk sac and a follow-up scan obtained at least 11 days later does not show an embryo with cardiac activity, the diagnosis of failed pregnancy is established (Fig. 2D and 2E; also see Fig. S3 in the Supplementary Appendix).

OTHER SUSPICIOUS FINDINGS

Several ultrasonographic findings early in the first trimester have been reported as abnormal. These include an “empty” amnion,³⁸ an enlarged yolk sac,³⁹ and a small gestational sac.⁴⁰ Criteria

for these abnormal findings are presented in Table 2. Because none of these signs have been extensively studied, they are considered to be suspicious for, though not diagnostic of, failed pregnancy.

DIAGNOSING AND RULING OUT A VIABLE INTRAUTERINE PREGNANCY IN A WOMAN WITH A PREGNANCY OF UNKNOWN LOCATION

The evaluation and management of a pregnancy of unknown location have received considerable attention, with various flow charts and mathematical models proposed for use in this context.^{41,42} Our intent here is not to review the broad topic of pregnancy of unknown location, but instead to focus on one important element: the role of an hCG level at a single point in time in diagnosing or ruling out a viable intrauterine pregnancy and in guiding patient-care decisions.

The hCG levels in viable intrauterine pregnancies, nonviable intrauterine pregnancies, and ectopic pregnancies have considerable overlap, so a single hCG measurement does not distinguish reliably among them.^{2,4,43} Considerable research during the past 30 years has sought to determine the discriminatory hCG level: the value above which an intrauterine gestational sac is consistently seen on ultrasonography in normal pregnancies. An early study, based on transabdominal ultrasonography, put the level at 6500 mIU per milliliter.⁴⁴ With improvements in ultrasonographic technology, including the introduction of transvaginal ultrasonography, gestational sacs became detectable earlier in pregnancy, and the reported discriminatory hCG level was brought down to 1000 to 2000 mIU per milliliter.⁴⁵⁻⁴⁷ As with the crown-rump length and mean sac diameter, however, more recent research has shown that previously accepted values for the discriminatory hCG level are not as reliable for ruling out a viable pregnancy as originally thought.

One reason for the lower reliability of the discriminatory hCG level today than was reported in the past may be the fact that multiple gestations, which are associated with higher hCG levels at a given stage of pregnancy than are singleton gestations, are more common now than they were 20 to 30 years ago. Failure of the discriminatory hCG level to rule out a viable intrauterine pregnancy, however, has

been seen in singleton as well as multiple gestations. Several studies have documented cases in which an embryo with cardiac activity was seen on follow-up ultrasonography after initial ultrasonography showed no gestational sac with an hCG level above 2000 mIU per milliliter^{12,48,49} and even above 3000 mIU per milliliter.^{12,48}

In a woman with a pregnancy of unknown location whose hCG level is more than 2000 mIU per milliliter, the most likely diagnosis is a nonviable intrauterine pregnancy, occurring approximately twice as often as ectopic pregnancy.⁵⁰ Ectopic pregnancy, in turn, occurs approximately 19 times as often as a viable intrauterine pregnancy when the hCG level is 2000 to 3000 mIU per milliliter and the uterus is empty, and 70 times as often as a viable intrauterine pregnancy when the hCG level is more than 3000 mIU per milliliter with an empty uterus. (These latter estimates are based on data from one institution assessing ectopic pregnancies¹⁹ and viable intrauterine pregnancies¹² in relation to hCG levels in women with an empty uterus.)

On the basis of these values, among women with a pregnancy of unknown location and hCG levels of 2000 to 3000 mIU per milliliter, there will be 19 ectopic pregnancies and 38 nonviable intrauterine pregnancies for each viable intrauterine pregnancy. Thus, the likelihood of a viable intrauterine pregnancy for such women is $[1 \div (1 + 19 + 38)]$, or approximately 2%. If we use the same reasoning for women with a preg-

nancy of unknown location and hCG levels of more than 3000 mIU per milliliter, the likelihood of a viable intrauterine pregnancy is $[1 \div (1 + 70 + 140)]$, or approximately 0.5%.

We recognize that these estimates of the likelihood of a viable intrauterine pregnancy in a woman with a pregnancy of unknown location whose hCG level is 2000 mIU per milliliter or higher are not highly precise, given the limitations of the available data, but there are a number of reasons why presumptive treatment for ectopic pregnancy with the use of methotrexate or other pharmacologic or surgical means is inappropriate if the woman is hemodynamically stable. First, as noted above, there is a chance of harming a viable intrauterine pregnancy, especially if the hCG level is 2000 to 3000 mIU per milliliter. Second, the most likely diagnosis is nonviable intrauterine pregnancy (i.e., failed pregnancy),⁵⁰ and methotrexate is not an appropriate treatment for a woman with this diagnosis. Third, there is limited risk in taking a few extra days to make a definitive diagnosis in a woman with a pregnancy of unknown location who has no signs or symptoms of rupture and no ultrasonographic evidence of ectopic pregnancy. Fourth, the progression of hCG values over a period of 48 hours provides valuable information for diagnostic and therapeutic decision making.^{4,51} Thus, it is generally appropriate to do additional testing before undertaking treatment for ectopic pregnancy in a hemodynamically stable patient (Table 3).^{2,43,52}

Table 3. Diagnostic and Management Guidelines Related to the Possibility of a Viable Intrauterine Pregnancy in a Woman with a Pregnancy of Unknown Location.*

Finding	Key Points
No intrauterine fluid collection and normal (or near-normal) adnexa on ultrasonography†	<p>A single measurement of hCG, regardless of its value, does not reliably distinguish between ectopic and intrauterine pregnancy (viable or nonviable).</p> <p>If a single hCG measurement is <3000 mIU/ml, presumptive treatment for ectopic pregnancy with the use of methotrexate or other pharmacologic or surgical means should not be undertaken, in order to avoid the risk of interrupting a viable intrauterine pregnancy.</p> <p>If a single hCG measurement is ≥3000 mIU/ml, a viable intrauterine pregnancy is possible but unlikely. However, the most likely diagnosis is a nonviable intrauterine pregnancy, so it is generally appropriate to obtain at least one follow-up hCG measurement and follow-up ultrasonogram before undertaking treatment for ectopic pregnancy.</p>
Ultrasonography not yet performed	<p>The hCG levels in women with ectopic pregnancies are highly variable, often <1000 mIU/ml, and the hCG level does not predict the likelihood of ectopic pregnancy rupture. Thus, when the clinical findings are suspicious for ectopic pregnancy, transvaginal ultrasonography is indicated even when the hCG level is low.</p>

* Criteria are from the Society of Radiologists in Ultrasound Multispecialty Consensus Conference on Early First Trimester Diagnosis of Miscarriage and Exclusion of a Viable Intrauterine Pregnancy, October 2012.

† Near-normal (i.e., inconsequential) adnexal findings include corpus luteum, a small amount of free pelvic fluid, and paratubal cyst.

Women with ectopic pregnancies have highly variable hCG levels, often less than 1000 mIU per milliliter,^{43,53,54} and the hCG level does not predict the likelihood of ectopic pregnancy rupture.⁵⁵ That is, a single hCG value, even if low, does not rule out a potentially life-threatening ruptured ectopic pregnancy. Hence, ultrasonography is indicated in any woman with a positive pregnancy test who is clinically suspected of having an ectopic pregnancy.

CONCLUSIONS

A false positive diagnosis of nonviable pregnancy early in the first trimester — incorrectly diagnosing pregnancy failure in a woman with an intrauterine gestational sac or ruling out viable intrauterine gestation in a woman with a pregnancy of unknown location — can prompt interventions that damage a pregnancy that might have had a normal outcome. Recent research has shown the need to adopt more stringent criteria for the diagnosis of nonviability in order to minimize or avoid false positive test results. The guidelines presented here, if promulgated widely to practitioners in the vari-

ous specialties involved in the diagnosis and management of problems in early pregnancy, would improve patient care and reduce the risk of inadvertent harm to potentially normal pregnancies.

Supported by funding from the National Institute for Health Research Biomedical Research Centre based at Imperial College Healthcare National Health Service Trust and Imperial College London (to Dr. Bourne).

Dr. Benacerraf reports receiving lecture fees from World Class CME and the International Institute for Continuing Medical Education and travel reimbursement from GE Healthcare. Dr. Benson reports receiving fees for expert testimony in medical malpractice cases regarding standard of care for interpretation of ultrasonographic examinations and lecture fees from the International Institute for Continuing Medical Education and the Institute for Advanced Medical Education. Dr. Doubilet reports receiving fees for expert testimony in medical malpractice cases regarding standard of care for interpretation of ultrasonographic examinations and lecture fees from the International Institute for Continuing Medical Education. Dr. Filly reports receiving fees for expert testimony in medical malpractice cases as an expert in diagnostic sonography and lecture fees from World Class CME. He also reports being co-holder of a patent for a needle-guide device used for venous access under ultrasonographic guidance. Dr. Goldstein reports receiving consulting fees from Cook OB/GYN, Pfizer, Shionogi, and Bayer and lecture fees from Merck and Warner Chilcott. Dr. Lyons reports receiving lecture fees from GE Medical Systems and holding stock in Zonare Medical Systems. No other potential conflict of interest relevant to this article was reported.

Disclosure forms provided by the authors are available with the full text of this article at NEJM.org.

REFERENCES

- Creanga AA, Shapiro-Mendoza CK, Bish CL, Zane S, Berg CJ, Callaghan WM. Trends in ectopic pregnancy mortality in the United States, 1980-2007. *Obstet Gynecol* 2011;117:837-43.
- Barnhart KT. Ectopic pregnancy. *N Engl J Med* 2009;361:379-87.
- Doubilet PM, Benson CB. First, do no harm . . . to early pregnancies. *J Ultrasound Med* 2010;29:685-9.
- Barnhart KT. Early pregnancy failure: beware of the pitfalls of modern management. *Fertil Steril* 2012;98:1061-5.
- Nurmohamed L, Moretti ME, Schechter T, et al. Outcome following high-dose methotrexate in pregnancies misdiagnosed as ectopic. *Am J Obstet Gynecol* 2011;205(6):533.e1-533.e3.
- Shwayder JM. Waiting for the tide to change: reducing risk in the turbulent sea of liability. *Obstet Gynecol* 2010;116:8-15.
- Misdiagnosed ectopic, given methotrexate. Facebook website (<http://www.facebook.com/groups/misdiagnosedectopic/>).
- Doubilet P. A mathematical approach to interpretation and selection of diagnostic tests. *Med Decis Making* 1983;3:177-95.
- Jeve Y, Rana R, Bhide A, Thangaratnam S. Accuracy of first trimester ultrasound in the diagnosis of early embryonic demise: a systematic review. *Ultrasound Obstet Gynecol* 2011;38:489-96.
- Abdallah Y, Daemen A, Kirk E, et al. Limitations of current definitions of miscarriage using mean gestational sac diameter and crown-rump length measurements: a multicenter observational study. *Ultrasound Obstet Gynecol* 2011;38:497-502.
- Hamilton J, Hamilton J. The 6 mm crown-rump length threshold for detecting fetal heart movements — what is the evidence? *Ultrasound Obstet Gynecol* 2011;38:Suppl 1:7. abstract.
- Doubilet PM, Benson CB. Further evidence against the reliability of the human chorionic gonadotropin discriminatory level. *J Ultrasound Med* 2011;30:1637-42.
- Thilaganathan B. The evidence base for miscarriage diagnosis: better late than never. *Ultrasound Obstet Gynecol* 2011;38:487-8.
- Bree RL, Edwards M, Böhm-Velez M, Beyler S, Roberts J, Mendelson EB. Transvaginal sonography in the evaluation of normal early pregnancy: correlation with hCG level. *AJR Am J Roentgenol* 1989;153:75-9.
- Goldstein I, Zimmer EA, Tamir A, Peretz BA, Paldi E. Evaluation of normal gestational sac growth: appearance of embryonic heartbeat and embryo body movements using the transvaginal technique. *Obstet Gynecol* 1991;77:885-8.
- Bradley WG, Fiske CE, Filly RA. The double sac sign of early intrauterine pregnancy: use in exclusion of ectopic pregnancy. *Radiology* 1982;143:223-6.
- Yeh H-C, Goodman JD, Carr L, Rabinowitz JG. Intradecidual sign: a US criterion of early intrauterine pregnancy. *Radiology* 1986;161:463-7.
- Doubilet PM, Benson CB. Double sac sign and intradecidual sign in early pregnancy: interobserver reliability and frequency of occurrence. *J Ultrasound Med* 2013;32:1207-14.
- Benson CB, Doubilet PM, Peters HE, Frates MC. Intrauterine fluid with ectopic pregnancy: a reappraisal. *J Ultrasound Med* 2013;32:389-93.
- Barnhart K, van Mello NM, Bourne T, et al. Pregnancy of unknown location: a consensus statement of nomenclature, definitions, and outcome. *Fertil Steril* 2011;95:857-66.
- Mueller CE. Intrauterine pseudogestational sac in ectopic pregnancy. *J Clin Ultrasound* 1979;7:133-6.
- Ackerman TE, Levi CS, Lyons EA, Dashefsky SM, Lindsay DJ, Holt SC. Decidual cyst: endovaginal sonographic sign of ectopic pregnancy. *Radiology* 1993;189:727-31.
- Levi CS, Lyons EA, Zheng XH, Lindsay DJ, Holt SC. Endovaginal ultrasound: demonstration of cardiac activity in embryos of less than 5.0 mm in crown-rump length. *Radiology* 1990;176:71-4.

24. Goldstein SR. Significance of cardiac activity on endovaginal ultrasound in very early embryos. *Obstet Gynecol* 1992;80:670-2.
25. Brown DL, Emerson DS, Felker RE, Cartier MS, Smith WC. Diagnosis of embryonic demise by endovaginal sonography. *J Ultrasound Med* 1990;9:631-6.
26. Pennell RG, Needleman L, Pajak T, et al. Prospective comparison of vaginal and abdominal sonography in normal early pregnancy. *J Ultrasound Med* 1991;10:63-7.
27. AIUM Practice Guideline for the performance of pelvic ultrasound examinations. *J Ultrasound Med* 2010;29:166-72.
28. ACOG Practice Bulletin No. 101: ultrasound in pregnancy. *Obstet Gynecol* 2009;113:451-61.
29. Levi CS, Dashefsky SM, Lyons EA, Holt SC, Lindsay DJ. First trimester ultrasound. In: McGahan JP, Goldberg BB, eds. *Diagnostic ultrasound: a logical approach*. Philadelphia: Lippincott-Raven, 1998:127-53.
30. Moore C, Promes SB. Ultrasound in pregnancy. *Emerg Clin North Am* 2004;22:697-722.
31. Deutchman M, Tubay AT, Turok DK. First trimester bleeding. *Am Fam Physician* 2009;79:985-94.
32. Pexsters A, Luts J, van Schoubroeck D, et al. Clinical implications of intra- and interobserver reproducibility of transvaginal sonographic measurements of gestational sac and crown-rump length at 6-9 weeks' gestation. *Ultrasound Obstet Gynecol* 2011;38:510-5.
33. Levi CS, Lyons EA, Lindsay DJ. Early diagnosis of nonviable pregnancy with endovaginal US. *Radiology* 1988;167:383-5.
34. Tongsong T, Wanapirak C, Sirsomboon J, Sirichotiyakul S, Polsrisuthikul T, Pongsatha S. Transvaginal ultrasound in threatened abortions with empty gestational sacs. *Int J Gynaecol Obstet* 1994;46:297-301.
35. Rowling SE, Coleman BG, Langer JE, Arger PH, Nisenbaum HL, Horii SC. First-trimester US parameters of failed pregnancy. *Radiology* 1997;203:211-7.
36. Abdallah Y, Daemen A, Guha S, et al. Gestational sac and embryonic growth are not useful as criteria to define miscarriage: a multicenter study. *Ultrasound Obstet Gynecol* 2011;38:503-9.
37. Savitz DA, Terry JW Jr, Dole N, Thorp JM Jr, Siega-Riz AM, Herring AH. Comparison of pregnancy dating by last menstrual period, ultrasound scanning, and their combination. *Am J Obstet Gynecol* 2002;187:1660-6.
38. Yegul NT, Filly RA. Further observations on the "empty amnion sign." *J Clin Ultrasound* 2010;38:113-7.
39. Lindsay DJ, Lovett IS, Lyons EA, et al. Yolk sac diameter and shape at endovaginal US: predictors of pregnancy outcome in the first trimester. *Radiology* 1992;183:115-8.
40. Bromley B, Harlow BL, Laboda LA, Benacerraf BR. Small sac size in the first trimester: a predictor of poor fetal outcome. *Radiology* 1991;178:375-7.
41. Condous G, Van Calster B, Kirk E, et al. Prediction of ectopic pregnancy in women with a pregnancy of unknown location. *Ultrasound Obstet Gynecol* 2007;29:680-7.
42. Kirk E, Condous G, Van Calster B, Van Huffel S, Timmerman D, Bourne T. Rationalizing the follow-up of pregnancies of unknown location. *Hum Reprod* 2007;22:1744-50.
43. Condous G, Kirk E, Lu C, et al. Diagnostic accuracy of varying discriminatory zones for the prediction of ectopic pregnancy in women with a pregnancy of unknown location. *Ultrasound Obstet Gynecol* 2005;26:770-5.
44. Kadar N, DeVore G, Romero R. Discriminatory hCG zone: its use in the sonographic evaluation for ectopic pregnancy. *Obstet Gynecol* 1981;58:156-61.
45. Bree RL, Edwards M, Bohm-Vélez M, Beyler S, Roberts J, Mendelson EB. Transvaginal sonography in the evaluation of early pregnancy: correlation with hCG level. *AJR Am J Roentgenol* 1989;153:75-9.
46. Bernaschek G, Rudelstorfer R, Csaicsich P. Vaginal sonography versus serum human chorionic gonadotropin in early detection of pregnancy. *Am J Obstet Gynecol* 1988;158:608-12.
47. Bateman BG, Nunley WC Jr, Kolp LA, Kitchin JD III, Felder R. Vaginal sonography findings and hCG dynamics of early intrauterine and tubal pregnancies. *Obstet Gynecol* 1990;75:421-7.
48. Mehta TS, Levine D, Beckwith B. Treatment of ectopic pregnancy: is a human chorionic gonadotropin level of 2000 mIU/ml a reasonable threshold? *Radiology* 1997;205:569-73.
49. Connolly A, Ryan DH, Stuebe AM, Wolfe HM. Reevaluation of discriminatory and threshold levels for serum hCG in early pregnancy. *Obstet Gynecol* 2013;121:65-70.
50. Shaunik A, Kulp J, Appleby DH, Sammel MD, Barnhart KT. Utility of dilation and curettage in the diagnosis of pregnancy of unknown location. *Am J Obstet Gynecol* 2011;204(2):130.e1-136.e1.
51. Bignardi T, Condous G, Alhamdan D, et al. The hCG ratio can predict the ultimate viability of the intrauterine pregnancies of uncertain viability in the pregnancy of unknown location population. *Hum Reprod* 2008;23:1964-7.
52. Sagili H, Mohamed K. Pregnancy of unknown location: an evidence-based approach to management. *Obstet Gynaecol* 2008;10:224-30.
53. Adhikari S, Blaivas M, Lyon M. Diagnosis and management of ectopic pregnancy using bedside transvaginal ultrasonography in the ED: a 2-year experience. *Am J Emerg Med* 2007;25:591-6.
54. Hahn SA, Lavonas EJ, Mace SE, Napoli AM, Fesmire FM. Critical issues in the initial evaluation and management of patients presenting to the emergency department in early pregnancy. *Ann Emerg Med* 2012;60:381-90.
55. Galstyan K, Kurzel R. Serum beta-hCG titers do not predict ruptured ectopic pregnancy. *Int J Fertil Womens Med* 2006;51:14-6.

Copyright © 2013 Massachusetts Medical Society.

IMAGES IN CLINICAL MEDICINE

The *Journal* welcomes consideration of new submissions for Images in Clinical Medicine. Instructions for authors and procedures for submissions can be found on the *Journal's* website at NEJM.org. At the discretion of the editor, images that are accepted for publication may appear in the print version of the *Journal*, the electronic version, or both.